

Double-bundle anterior cruciate ligament reconstruction: a short-term study

Hossam A. ElBigawi, Mohamed G. Montaser, Abdelsamee M. Halawa, Mohammed S. Shawki

Department of Orthopaedic Surgery, Faculty of Medicine, Benha University, Qalyubi, Egypt

Correspondence to Hossam El Bigawi, MD, Department of Orthopaedic Surgery, Faculty of Medicine, Benha University, Qalyubi, Egypt
Tel: +01224098401;
e-mail: hossammedin@yahoo.com

Received 3 August 2011

Accepted 20 December 2011

Egyptian Orthopedic Journal 2013, 48:376-380

Background

In recent years, there is an increasing interest in double-bundle (DB) anterior cruciate ligament (ACL) reconstruction to improve the anatomical, biomechanical, and clinical outcome of the procedure.

Objectives

The aim of the study was to evaluate the outcome of arthroscopic DB ACL reconstruction using the four-tunnel technique with autograft hamstring tendons for athletic patients.

Patients and methods

Fifteen athletic male patients suffering from ACL injury with a mean age at the time of operation of 24.3 years (average 18–34 years) were operated upon using four-tunnel technique, and fixation was carried out by two femoral end buttons and two tibial interference screws.

Results

After a mean follow-up period of 26 months (range 12–42 months), according to the International Knee Documentation Committee score, 14 patients (93.3%) became normal and near normal, whereas one patient (6.7%) was abnormal. The Lysholm score changed from 56 points preoperative (range 30–72) to 93 points (range 45–100) at the end of follow-up. Thirteen patients (86.6%) had normal Lachman and anterior drawer tests results. Twelve patients had negative pivot shift test. Nine patients (60%) had near normal thigh girth in comparison with the healthy side. All 15 patients reached 100% range of motion in comparison with the other healthy side at the end of follow-up.

Conclusion

ACL reconstruction with the DB technique is good for stability of the knee. Long-term studies should be performed and the number of patients should be increased.

Keywords:

double-bundle, ACL reconstruction, short-term study

Egypt Orthop J 48:376-380

© 2013 The Egyptian Orthopaedic Association
1110-1148

Introduction

The anterior cruciate ligament (ACL) reconstruction is a common procedure. The conventional arthroscopic transtibial ACL reconstruction technique is still the most frequently performed operation. However, osteoarthritic changes at midterm follow-up [1] and knee pain or residual instability are still observed. A recent meta-analysis has shown that no more than 60% of the patients make a full recovery after single-bundle ACL reconstruction [2–4].

In recent years, there is an increasing interest in double-bundle (DB) ACL reconstruction to improve the anatomic [5], biomechanical [6], and clinical outcome of the procedure. Usually, the reconstruction of the anteromedial (AM) and posterolateral (PL) bundle is performed with tendon grafts, for example, the autologous semitendinosus and gracilis tendons [7]. The success of reconstruction depends on three major factors: biological, mechanical, and rehabilitational. The surgical outcome depends on the ability of the

graft to reproduce the restraining action of the ACL and restore the normal kinematics of the knee [8].

The aim of this study was to evaluate the outcome results of arthroscopic DB ACL reconstruction using the four-tunnel technique with autograft hamstring tendons for athletic patients suffering from unstable knee due to ACL injury, using the traditional methods of evaluation.

Patients and methods

Between 2006 and 2008, 15 athletic male patients suffering from ACL injury were operated upon in Benha University Hospital. All patients were available for the postoperative follow-up evaluation for a duration between 12 and 42 months (mean 26 months).

The selection criteria of our patients depend mainly upon careful meticulous history-taking, analysis of patient's complaint, the preinjury level of activity, and

clinical examination. Radiography and MRI were performed routinely for every patient, and the diagnosis was carried out on the basis of clinical correlation.

The mean age of the patients at the time of operation was 24.3 years (range 18–32.6 years). The average time passed between the injury and the operation was 9.6 months (range 3–17 months). The right side was affected in nine patients and the left side was affected in the other six patients. The cause of injury was related to sport in all 15 patients.

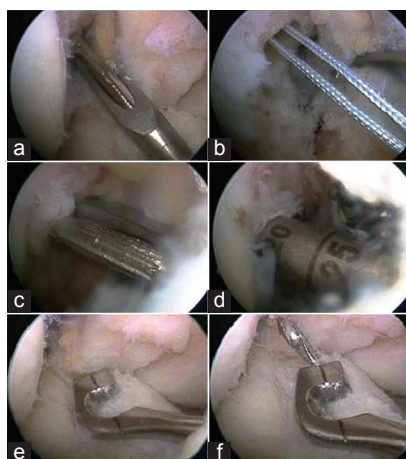
Clinically, all patients gave history of giving way, 10 patients gave history of pain, and seven patients gave a clear history of locking, which was attributed to associated meniscal lesions. All patients had positive Lachman and pivot shift tests. The Lachman test was graded 2+ (6–10 mm) in eight patients and 3+ (>10 mm) in seven patients. The pivot shift was graded 2+ (clunk) in 10 patients and 3+ (gross) in the other five patients.

According to the MRI examination of the patients, six patients only had meniscal injury, three patients had medial meniscus injury, two had lateral, and one patient had both medial and lateral meniscal injuries.

Surgical technique

All patients were operated upon under spinal anesthesia. They received preoperative antibiotic in the form of third-generation cephalosporin before the application of the tourniquet. Diagnostic arthroscopy was performed first and if there was a meniscal injury, meniscectomy was performed. Thereafter, harvesting the tendons of the semitendinosus and gracilis muscles for grafting was carried out. The notch was prepared.

Figure 1



(a–d) Preparation of the femoral tunnels: (a) insertion of the guide pin for the anteromedial bundle, (b) the tunnel after drilling, (c) insertion of the guide pin for posterolateral bundle, and (e and f) insertion of the guide pins for tibial tunnels.

Two femoral tunnels were made first through the AM portals (Fig. 1a–d) followed by two tibial tunnels (Fig. 1e and f). After preparation of the tendons for grafting, the grafts were passed through the tunnels and hanged on the distal femoral cortex by the end buttons (Fig. 2a). The distal ends of the grafts were fixed to the tibia by two interference screws (Fig. 2b). Suction drain was used in some patients at the graft harvesting site in some cases only. Skin closure was performed, then crepe bandage was rolled around the knee and the knee was put in knee brace, which was locked in full extension.

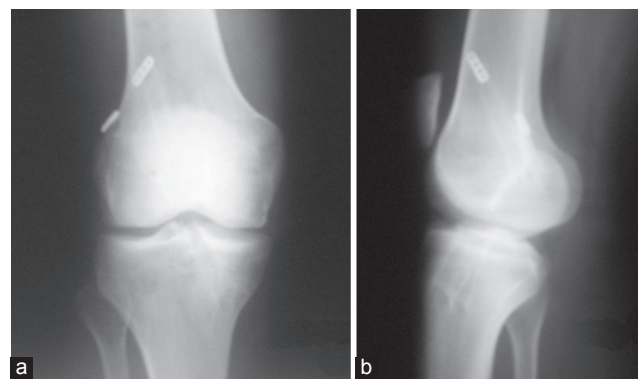
Postoperative program

Physiotherapeutic exercise program was started from the first postoperative day including treatment to reduce swelling and promote movement using the CPM. The joint should gain pain-free flexion up to 90° in the first postoperative week. Straight-ahead walking was permitted from the postoperative week, if the gait pattern was normal. Postoperative rehabilitation program popularized by Shelbourne *et al.* [9,10] was used until complete recovery. The physiotherapy program was supervised by the operating team surgeons. The patients were reviewed every week during the first month, every 2 weeks during the second month, and by the end of the third month.

Evaluation

Patients were evaluated before operation and after operation at the end of follow-up period according to the subjective methods, using the International Knee Documentation Committee (IKDC) [11] score system and Lysholm [12] score system, and objective methods including the Lachman test, pivot shift test, anterior drawer test, range of motion, and postoperative thigh girth. Nonparametric analysis was performed with the Wilcoxon signed-rank test for comparison of preoperative

Figure 2



Postoperative radiographs after fixation by (a) femoral endobuttons and (b) two tibial screws.

and postoperative scores. The Pearson correlation coefficient was used for correlation analysis. *P*-value less than 0.05 was considered statistically significant.

Results

Subjective assessment

According to the IKDC score (Table 1), 11 patients (73.3%) were normal, three patients (20%) were near normal, and one patient (6.7%) was abnormal at the end of follow-up period. The Lysholm score changed significantly ($P < 0.002$) from 56 points preoperative (range 30–72) to 93 points (range 45–100) by the end of follow-up.

Five patients (33.3%) suffered mild pain postoperative for few weeks. This pain was relieved by NSAIDs in four patients. This pain was related to meniscal excision. Only one patient was complaining of pain at the end of follow-up period.

By the end of follow-up period, two patients complained of giving way on severe exertion. There were no swelling and no graft harvest site pathology. All patients returned to their preinjury level of activity and sports except one patient.

Objective assessment

By the end of follow-up period, 13 patients (86.6%) had normal Lachman and anterior drawer tests results, one patient had near normal result, and the other patient had abnormal tests result in comparison with the healthy side.

Twelve (80%) patients had negative pivot shift test, two patients were near normal, and one patient was still abnormal but in slight degree in comparison with the preoperative results (Table 2).

Nine patients (60%) had near normal thigh girth in comparison with the healthy side, whereas three patients (20%) had 1 cm difference, two patients (13%) had 2 cm difference, and one patient (6.7%) had 3 cm difference when compared with the healthy side.

All 15 patients had 100% range of motion in comparison with the other healthy side at the end of follow-up period. There were four patients suffering from extension lag in the first few months after operation, but they gained full extension with physiotherapy (Fig. 3).

Complications

There were no intraoperative complications in all 15 patients. One patient was complicated by severe

effusion, and he was in need for aspiration and cold fomentation. However, no massive effusion occurred in any other patient apart from mild to moderate effusion during the first 3 months postoperative. Two patients suffered from postoperative superficial wound infection of the donor site. They were in need to be hospitalized for more days and received antibiotics and daily dressing, and they relived within few days. There was no intra-articular infection or deep venous thrombosis.

Discussion

The recent biomechanical studies have revealed some interesting insight regarding the role of PL bundle in restoring knee stability. Biomechanical studies have shown that standard ACL reconstructions using either quadruple-loop hamstring or bone-patellar tendon-bone grafts are successful at restoring anterior stability to the knee [13].

In the development of the DB technique, some of these techniques used one tibial and one femoral

Table 1 Postoperative IKDC score

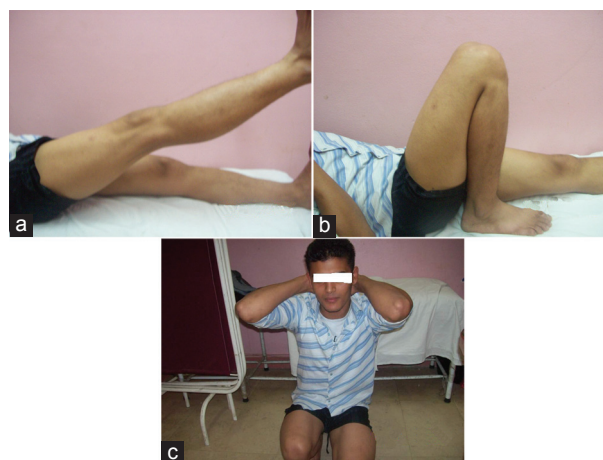	Number of patients [n (%)]
Normal	11 (73.3)
Near normal	3 (20)
Abnormal	1 (6.7)

IKDC, International knee documentation committee.

Table 2 Postoperative lachman and pivot shift tests

Test	Normal [n (%)]	Near normal [n (%)]	Abnormal [n (%)]
Lachman test	13 (86.6)	1 (6.7)	1 (6.7)
Pivot shift test	12 (80)	2 (13.3)	1 (6.7)

Figure 3



Range of motion.

tunnel, others used one tibial and two femoral tunnels or vice versa, and the rest used two femoral and two tibial tunnels [14].

According to the dimensions of the femoral and tibial insertion site of the ACL, the restoration of the AM and the PL bundle necessitates not only two tibial and two femoral tunnels, but also an anatomic placement of each tunnel. In numerous ACL 'double-bundle' techniques, however, less attention was given to restore the footprint of the PL bundle from an anatomic point of view [14]. We used two femoral tunnels and two tibial tunnels to restore the anatomy of the ligament.

Our study included 15 male patients. Male individuals are more susceptible to injuries during sport, as they are more aggressive and participate in various activities. The mean age at surgery was 24.3 years, ranging from 18 to 32.6 years. This age reflects the highest level of activities in the human life. The causative trauma was sport-related, and this means that the main cause of ACL injury is sport-related activities and these people usually seek medical advice and proceed in the definitive management.

Giving way was the leading complaint for medical advice in all patients as we proceed to treat instability. Other symptoms were related to meniscal injury in seven patients, approved by MRI examination in six patients only. There was statistical difference between the preoperative and postoperative results of giving way. In all, 86.6% of the patients had no record of giving way postoperatively. Only two patients still had giving way on severe exertion at the end of follow-up.

The final subjective results as measured by IKDC at the last visit of follow-up revealed that 14 patients (93.3%) were normal and near normal. The documented clinical success rates of modern techniques of single bundle have varied between 69 and 95% in various series [15].

In addition, the Lysholm score changed from 56 points preoperative (range 30–72) to 93 points (range 45–100) by the end of follow-up, and this reflects the satisfaction of the patients after the reconstruction.

With respect to the Lachman and pivot shift tests, there was significant difference between the preoperative and postoperative test at the end of follow-up. Fourteen patients had normal and near normal Lachman test and pivot shift test results. These results reflect the high stability after the operation.

The most important parameters used by Fu *et al.* [16] to evaluate the results of his cases of DB ACL reconstruction are the range of motion, ligamentous laxity, and the patient-oriented outcome.

All 15 patients had 100% range of motion in comparison with the normal healthy side at the end of follow-up period.

The postoperative thigh girth in nine patients (60%) was equal to the normal healthy side. This depends mainly on the postoperative physiotherapy.

Our results are comparable with results of the study that was presented by Colombet *et al.* [17]; the authors reported the outcome of four-tunnel DB ACL reconstruction, with hamstrings in 33 patients after an average of 24 months postoperatively. Fixation was by means of two femoral endobutton and two absorbable oversized interference screws on the tibial side. In all, 94% of the patients had returned to sports after an average of 9 months following surgery, 75% returned to their preinjury sports level, and 84% had a negative pivot shift test.

Conclusion

ACL reconstruction with the DB technique is good for stability of the knee. Long-term studies should be performed and the number of patients should be increased.

Acknowledgements

Conflicts of interest

There are no conflicts of interest.

References

- 1 Fithian DC, Paxton EW, Stone ML, Luetzow WF, Csintalan RP, Phelan D. Prospective trial of a treatment algorithm for the management of the anterior cruciate ligament-injured knee. *Am J Sports Med* 2005; 33:335–346.
- 2 Yunes M, Richmond JC, Engels EA, Pinczewski LA. Patellar versus hamstring tendons in anterior cruciate ligament reconstruction: a meta-analysis. *Arthroscopy* 2001; 17:248–257.
- 3 Biau DJ, Tournoux C, Katsahian S, Schranz P, Nizard R. ACL reconstruction: a meta-analysis of functional scores. *Clin Orthop* 2007; 458:180–187.
- 4 Kato Y, Hoshino Y, Ingham SJM, Fu FH. Anatomic double-bundle anterior cruciate ligament reconstruction. *J Orthop Sci* 2010; 15:269–276.
- 5 Amis AA, Zavras TD. Review: isometricity and graft placement during anterior cruciate ligament reconstruction. *Knee* 1995; 2:5–17.
- 6 Ristanis S, Stergiou N, Patras K, Vasiliadis HS, Giakas G, Georgoulis AD. Excessive tibial rotation during high demand activities is not restored by anterior cruciate ligament reconstruction. *Arthroscopy* 2005; 21:1323–1329.
- 7 Siebold RH, Thierjung K, Cafaltzis E, Hoeschele J, Tao T. ?. *Knee Surg Sports Traumatol Arthrosc* 2008; 16:386–392.
- 8 G Cerulli, G Zamarra, F Vercillo, F Pelosi. ACL reconstruction with 'the original all-inside technique'. *Knee Surg Sports Traumatol Arthrosc* 2011; 19:829–831.
- 9 Shelbourne D, Klootwyk T, DeCarlo M. Rehabilitation program for ACL reconstruction. *Sports Med Arthrosc Rev* 1997; 5:77.
- 10 Shelbourne K, Nitz P. Accelerated rehabilitation after anterior cruciate ligament reconstruction. *Am J Sports Med* 1990; 18:292–299.
- 11 Irrgang JJ, Ho H, Harner CD, Fu FH. Use of IKDC guidelines to assess outcome following ACL reconstruction. *Knee Surg Sports Traumatol Arthrosc* 1997; 6:107.

- 12 Tegner P, Lysholm J. Rating systems in the evaluation of knee ligament injuries. *Clin Orthop* 1985; 198:43.
- 13 Markolf KL, Park S, Jackson SR, McAllister DR. Simulated pivot-shift testing with single and double-bundle anterior cruciate ligament reconstructions. *J Bone Joint Surg Am* 2008; 90:1681–1689.
- 14 Lorenz S, Anetzberger H, Spang JT, Imhoff AB. Double-bundle technique — anatomic reconstruction of the anterior cruciate ligament. *Oper Orthop Traumatol* 2007; 19:473–488.
- 15 Vidal AF, Brucker PU, Fu FH. Anatomic double-bundle anterior cruciate ligament reconstruction using tibialis anterior tendon allografts. *Oper Tech Orthop* 2005; 15:140–145.
- 16 Fu FH, Smolinski P, Tashman S, Irrgang JJ, Moreland MS. Anatomic double bundle anterior cruciate ligament reconstruction study group 2007–2008 year review. *Pittsburgh Orthop J* 2008; 19:67–69.
- 17 Colombet P, Robinson J, Jambou S, Allard M, Bousquet V, de Lavigne C. Two-bundle four-tunnel anterior cruciate ligament reconstruction. *Knee Surg Sports Traumatol Arthrosc* 2006; 14:629–636.